［Original］

Trabecular Bone Volume Is Reduced, With Deteriorated Microstructure, With Aging in a Rat Model of Duchenne Muscular Dystrophy

Hinako Obara[1], Takafumi Tajima[1], Manabu Tsukamoto[1], Yoshiaki Yamanaka[1], Hitoshi Suzuki[1], Yukichi Zenke[2], Makoto Kawasaki[1], Karina Kouzaki[3], Koichi Nakazato[3], Kenji Hiranuma[3] and Akinori Sakai[1*]

[1] *Department of Orthopaedic Surgery, School of Medicine, University of Occupational and Environmental Health, Japan. Yahatanishi-ku, Kitakyushu 807-8555, Japan*
[2] *Department of Emergency Medicine, School of Medicine, University of Occupational and Environmental Health, Japan. Yahatanishi-ku, Kitakyushu 807-8555, Japan*
[3] *Graduate School of Health and Sport Science, Nippon Sport Science University, Japan. Setagaya-ku, Tokyo 158-8508, Japan*

Abstract **:** We aimed to clarify the effect of aging on trabecular bone volume and trabecular bone microstructure in a rat model of Duchenne muscular dystrophy (DMD). Six rats each of wild type (WT) and DMD model at 15 weeks of age, and 4 rats each at 30 weeks of age, were analyzed by dual energy X-ray absorptiometry and by micro-CT for analysis of trabecular and cortical bone of the femur. Bone mineral density was significantly lower in the DMD group than in the WT group at both 15 and 30 weeks of age. Micro-CT showed that trabecular bone volume and number were not significantly different between the two groups at 15 weeks, but at 30 weeks both were significantly lower in the DMD group than in the WT group. Connectivity density and structure model index were not significantly different between the two groups at 15 weeks, but at 30 weeks they differed significantly. No significant differences between the WT and DMD groups in cortical thickness and cortical area were evident at both 15 and 30 weeks. In conclusion, trabecular bone volume is significantly reduced, with deteriorated microstructure, with aging in a rat model of DMD.

Keywords **:** Duchenne muscular dystrophy, bone mineral density, trabecular bone, cortical bone, rat model.

（Received March 14, 2022, accepted May 11, 2022）

Introduction

Duchenne muscular dystrophy (DMD) is a hereditary disease characterized by progressive skeletal muscle degeneration and weakness, and is related to alterations in a protein called dystrophin that helps to keep muscle cells intact [1]. Lack of the dystrophin protein in muscle cells causes those cells to be fragile and easily damaged. DMD has an X-linked recessive inheritance pattern and thus primarily affects boys. DMD symptoms appear in early childhood and gradually worsen with increasing age.

DMD brings a significantly increased risk of bone loss. Patients with DMD develop osteoporosis and osteoporotic fractures [2]. Half these patients experience symptomatic fractures until 12.8 years of age

*Corresponding Author: Akinori Sakai, Department of Orthopaedic Surgery, School of Medicine, University of Occupational and Environmental Health, Japan. 1-1 Iseigaoka, Yahatanishi-ku, Kitakyushu 807-8555, Japan, Tel: +81-93-691-7444, Fax: +81-93-692-0184, E-mail: a-sakai@med.uoeh-u.ac.jp

[3]. Fracture probabilities at 6, 9, 12, and 15 years of age are 4%, 9%, 31%, and 60%, respectively, and accelerate around the time of ambulation loss (mean age: 11.8 years) [4]. A cross-sectional study revealed that bone mineral density (BMD) for total body, spine, heel, and forearm measurements was lower in patients with DMD than in healthy boys and that the differences increased with increasing age [5]. Lower limb BMD is significantly correlated with lower limb muscle strength in boys with DMD [6]. BMD Z-score was lower in patients with DMD than in healthy individuals for both spine and total body. In patients with DMD, spinal BMD was significantly lower in a steroid-treated group than in a group that did not receive steroids. However, knowledge about age-related alterations of bone volume and structure in patients with DMD is scarce.

Murine models of DMD have been developed to investigate treatment of the disease in humans [7−10]. A rat model of DMD can be generated with a CRISPR/Cas system, an RNA-based genomic engineering technique that can be adapted to rats [10, 11]. No dystrophin protein expression is apparent in immunoblotting or immunostaining analyses in any DMD-mutated rats. These DMD model rats are easier to breed and to handle than are golden retriever muscular dystrophy dogs [12, 13], and they show symptoms that are more similar to those in mdx mice [14, 15]. Mdx mice show weaker muscular degeneration and gradual recovery of muscular degeneration, with a peak at 4−8 weeks after birth. In rats, muscular degeneration continues to progress [10, 11]. Thus, compared with the mdx mouse model, the rat model of DMD shows disease characteristics and progression that more closely resemble those in human DMD. We therefore investigated bone volume and structure in mature DMD rats at 15 and 30 weeks of age. To the best our knowledge, no publication has so far reported on bone alteration with aging in DMD rats. The purpose of our study was to clarify the consequences of aging for bone volume and bone microstructure in DMD rats.

Materials and Methods

Animals

Using a CRISPR/Cas system, DMD rats were produced by Teijin Ltd. (Osaka, Japan) in the manner previously described [10, 11] and were provided to Koichi Nakazato at the Graduate School of Health and Sport Science, Nippon Sport Science University. Experiments using the DMD rats were carried out in the animal experimentation facility of Nippon Sport Science University, and all the experiments were approved by the Animal Experimental Committee of Nippon Sport Science University (no. 016-GR02). The procedures complied with the policies and regulations of the *Fundamental Guidelines for Proper Conduct of Animal Experiments and Related Activities in Academic Research Institutions*, published by the Ministry of Education, Culture, Sports, Science, and Technology, Japan (notification no. 71, 2006).

Femoral bone samples

Femoral bone samples were fixed in 70% ethanol for imaging analyses. Six male rats each of wild type (WT [CLEA Japan, Tokyo, Japan]) and DMD aged 15 weeks, and 4 male rats each of WT and DMD aged 30 weeks, were used for analyses.

Body weight and bone length

The body weight of the rats was measured just before euthanasia, and the length of the right femur was measured using digital calipers, as described previously [16].

BMD and bone microstructure

BMD (mg/cm^3) of the right femur was measured by dual energy X-ray absorptiometry (DXA) (DCS-600: Aloka, Tokyo, Japan). The distal metaphysis and diaphysis in the femurs were scanned by 3D micro computed tomography (micro-CT) (CosmoScan GX: Rigaku, Tokyo, Japan). The images were obtained using these parameters: 90 kV, 88 μA, 20 μm^3 voxel size.

On the micro-CT images, the distal metaphysis region of interest was located 3.0 mm from the growth plate in the femur, and the diaphysis region of interest was located 2.0 mm above and below the center of the femur length. The histomorphometric parameters in the trabecular and cortical bone of the femur were automatically measured by an analyzing tool (TRI/3D BON software, RATOC System Engineering Corp., Tokyo, Japan). The trabecular region was measured at

the distal metaphysis site to obtain the bone/tissue volume (BV/TV [%]), trabecular number (Tb.N [1/mm]), trabecular thickness (Tb.Th [mm]), and trabecular separation (Tb.Sp [mm]). The trabecular bone microstructure was evaluated for connectivity density (1/mm^3) and structure model index. The cortical region was measured at the diaphysis site to obtain the cortical thickness (Ct.Th [mm]), the cortical/total area (Ct.Ar/Tt.Ar [%]), the periosteal perimeter (Ps.Pm [mm]), and the endocortical perimeter (Ec.Pm [mm]). The abbreviations are based on the recommendations of the American Society for Bone and Mineral Research [17] and the micro-CT guidelines [18].

Statistical analysis

All results are expressed as means ± SE. Differences between the WT and DMD groups were analyzed using the Mann-Whitney *U*-test and $P<0.05$ was considered significant. The analysis was performed using the IBM SPSS Statistics software application (version 22.0: IBM Japan, Tokyo, Japan) on a Macintosh computer.

Results

Body weight and femoral bone size

There were significant differences in body weight between the WT and DMD groups at 15 and 30 weeks, with body weight being significantly lower in the DMD group than in the WT group. At 15 weeks, body weight in the WT group (mean ± standard error) was 495.9 g ± 16.7 g, and 336.5 g ± 30.2 g in the DMD group ($P<0.01$); at 30 weeks, it was 639.8 g ± 24.3 g in the WT group and 470.9 g ± 15.5 g in the DMD group ($P<0.01$).

Femoral bone length was significantly shorter in the DMD group than in the WT group at 15 weeks, but not at 30 weeks (Table 1). Bone length increased significantly in both groups from 15 to 30 weeks. The Ps.Pm and Ec.Pm were significantly shorter in the DMD group than in the WT group at 15 weeks, but not at 30 weeks (Table 1). The Ps.Pm increased significantly from 15 to 30 weeks in both groups. From 15 to 30 weeks, the Ec.Pm increased significantly in the DMD group, but not in the WT group.

Table 1. Femoral bone size

	15 weeks		30 weeks	
	WT	DMD	WT	DMD
Length (mm)	38.0±0.6	35.9±0.3*	40.7±0.5#	39.5±0.6#
Ps.Pm (mm)	13.1±0.2	12.3±0.2*	14.5±0.3#	14.0±0.3#
Ec.Pm (mm)	9.2±0.3	8.3±0.3*	9.9±0.3	9.9±0.3#

WT: wild-type, DMD: Duchenne muscular dystrophy. Ps.Pm: periosteal perimeter, Ec.Pm: endocortical perimeter. Each value is expressed as mean ± standard error. By Mann-Whitney *U*-test: *$P<0.05$ vs. WT, #$P<0.05$ vs. results at 15 weeks in the corresponding group.

Bone mineral density by DXA

BMD was significantly lower in the DMD group than in the WT group at 15 weeks and 30 weeks (Figure 1). BMD increased significantly from 15 to 30 weeks in both groups.

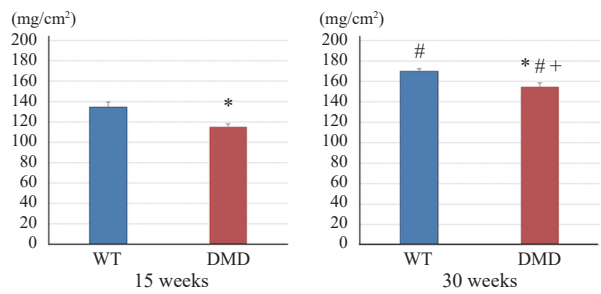

Figure 1. Bone mineral density of the total femur. Results from femurs obtained from 15-week-old rats, 6 each wild-type (WT) and Duchenne muscular dystrophy (DMD) model (left panel), and from 30-week-old rats, 4 WT and 4 DMD model (right panel). By Mann-Whitney *U*-test: *$P<0.05$ vs. WT. #$P<0.05$ vs. results at 15 weeks in the corresponding group. +$P<0.05$ vs. results in WT rats at 15 weeks.

Trabecular bone analysis

Sagittal micro-CT images of the distal metaphysis of the femur showed a decrease in trabecular bone volume and Tb.N in the DMD group compared with the WT group at 15 weeks, and even more obviously at 30 weeks (Figure 2).

The BV/TV and Tb.N were significantly lower in the DMD group than in the WT group at 30 weeks, but not at 15 weeks (Figure 3A, B). BV/TV and Tb.N increased significantly in the WT group, but not in the DMD group, from 15 to 30 weeks. Tb.Th did not differ between the WT and DMD groups, and did not change

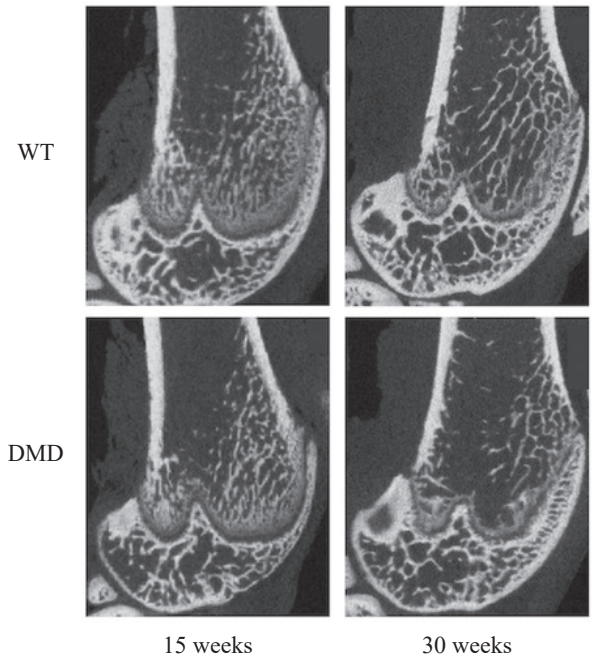

Figure 2. Sagittal images of distal femur by micro–computed tomography. Alteration in the microstructure of trabecular bone was observed from 15 weeks to 30 weeks in both the wild-type and Duchenne muscular dystrophy model rats.

from 15 to 30 weeks in either group (Figure 3C). At 15 weeks, the Tb.Sp in the DMD group did not differ from that in the WT group, but at 30 weeks, the Tb.Sp was significantly greater in the DMD group than in the WT group (Figure 3D). The Tb.Sp increased significantly in the DMD group from 15 to 30 weeks, but did not change in the WT group.

Trabecular bone microstructure

At 15 weeks, the connectivity density (Conn.D) and structure model index (SMI) did not differ between the WT and DMD groups; however, the Conn.D was significantly lower and the SMI was significantly greater in the DMD group than in the WT group at 30 weeks (Figure 4).

Cortical bone analysis

The Ct.Th and Ct.Ar/Tt.Ar did not differ between the WT and DMD groups at 15 and 30 weeks (Figure 5). The Ct.Th increased significantly from 15 to 30 weeks in both the WT and DMD groups. The Ct.Ar/Tt.Ar increased significantly from 15 weeks to 30 weeks in the WT group, but not in the DMD group.

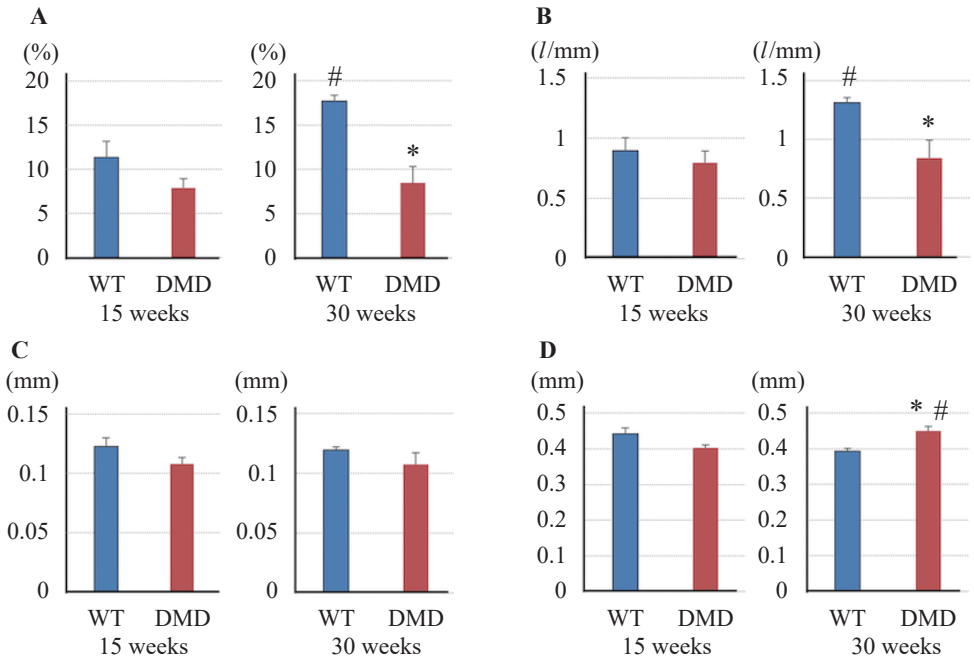

Figure 3. Trabecular bone volume and structure. A: Bone volume/tissue volume (BV/TV), B: trabecular number (Tb.N), C: trabecular thickness (Tb.Th), and D: trabecular separation (Tb.Sp) in wild-type (WT) and Duchenne muscular dystrophy (DMD) model rats at 15 weeks of age (6 rats in each group) and 30 weeks of age (4 rats in each group). By Mann-Whitney *U*-test: $^{*}P < 0.05$ vs. WT. $^{\#}P < 0.05$ vs. results at 15 weeks in the corresponding group.

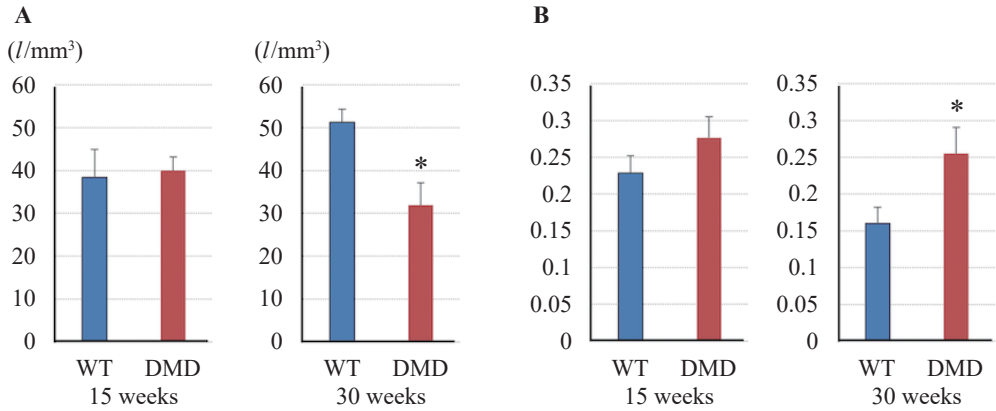

Figure 4. Trabecular bone microstructure. A: Connectivity density (Conn.D) and B: structure model index (SMI) in wild-type (WT) and Duchenne muscular dystrophy (DMD) model rats at 15 weeks of age (6 rats in each group) and 30 weeks of age (4 rats in each group). By Mann-Whitney *U*-test: $^{*}P < 0.05$.

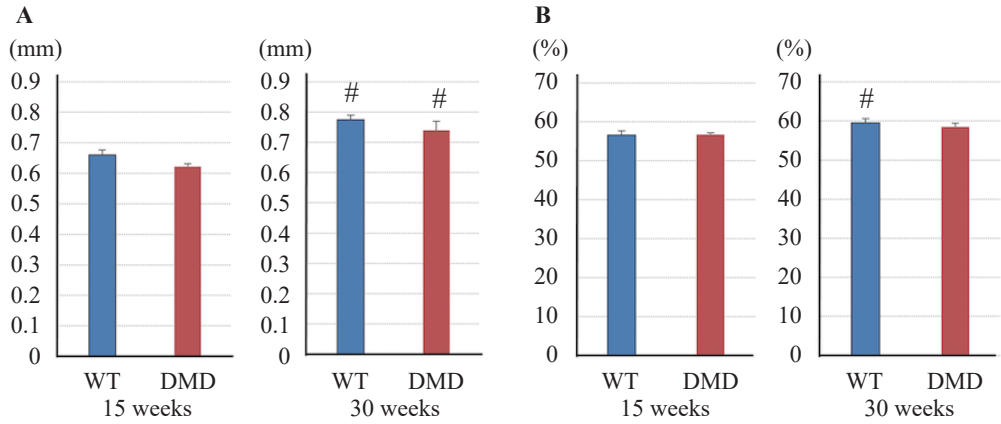

Figure 5. Cortical thickness and area. A: Cortical thickness (Ct.Th) and B: cortical area/total area (Ct.Ar/Tt.Ar) in wild-type (WT) and Duchenne muscular dystrophy (DMD) model rats at 15 weeks of age (6 rats in each group) and 30 weeks of age (4 rats in each group). By Mann-Whitney *U*-test: $^{\#}P < 0.05$ vs. results at 15 weeks in the corresponding group.

Discussion

This study clearly demonstrates that, with aging from 15 to 30 weeks in a rat model of DMD, trabecular bone volume and number decreased significantly, with deterioration of the trabecular microstructure as measured by connectivity density and structure model index. However, cortical thickness and area did not differ between the WT and DMD rats.

Although body weight was significantly lower in the DMD group than in the WT group at 15 and 30 weeks, femoral length, Ps.Pm, and Ec.Pm were lower in the DMD group than in the WT group at 15 weeks, but were similar in both groups at 30 weeks. At 30 weeks, BMD, BV/TV, and Tb.N were significantly lower in the DMD group than in the WT group, with deterioration of the trabecular microstructure being evident in the DMD group. On the other hand, with aging from 15 to 30 weeks, the Ps.Pm and Ec.Pm of the femoral diaphysis in the DMD group had caught up to the level seen in the WT group. The Ct.Th and Ct.Ar/Tt.Ar did not differ between the WT and DMD groups. Thus, the alterations in trabecular bone and cortical bone were quite different with aging from 15 to 30 weeks in the two groups.

The trabecular bone results at 30 weeks in our study are comparable to those observed in male mdx mice at 6 months of age [19]. Trabecular bone volume and Tb.N decreased significantly in mdx mice in comparison with WT mice, but Tb.Th was equal in those two groups. On the other hand, cortical bone results at 30 weeks in our study were different from those observed

in male mdx mice at 6 months of age. Although the Ct.Ar was not different in the DMD and WT rats, it was significantly lower in mdx mice than in WT mice.

The precise mechanism of the reduced trabecular bone volume, with deteriorated microstructure, with aging in DMD rats remains unknown. Given that muscle degeneration continues to progress in DMD rats such as those used in the present study [10, 11], weakened muscle contraction leads to less mechanical stimulation to bone. Decreased muscle function is known to contribute to BMD loss in patients with DMD [20]. Trabecular bone volume and structure might be more affected than cortical bone because of higher metabolic turnover in bone. The serum concentration of interleukin 6 has also been reported to be significantly higher in patients with DMD than in control participants [19]. Human primary osteoblasts from healthy donors incubated with 10% sera from patients with DMD showed decreased mineralized nodule formation. Systemic blood-borne factors, including interleukin 6, act as important mediators of bone loss in DMD [21]. Compared with cortical bone, trabecular bone might be more affected by circulating factors because of its exposure to more abundant blood flow. Bone loss in DMD can be improved with exogenously administered bisphosphonates, which works well for increasing trabecular bone volume in humans [22, 23] and animals [24] alike.

Dramatic loss of trabecular bone is observed after cessation of ambulation in patients with DMD [25]. Research has shown that, in boys with DMD, trabecular bone density was significantly lower at the metaphyseal radius and metaphyseal tibia than it was in healthy boys, but cortical bone density was similar at the diaphyseal radius and diaphyseal tibia. Compared with healthy boys, boys with DMD had a similar diaphyseal cross-sectional area and diaphyseal Ct.Th. Differences in cortical parameters were smaller than differences in trabecular parameters for boys with DMD compared with healthy boys. Moreover, during long-term glucocorticoid treatment, an investigation using high-resolution peripheral quantitative computed tomography demonstrated that trabecular microstructure indices at the distal radius were significantly lower, but that cortical volumetric BMD was significantly higher, in boys with DMD compared with healthy boys [26]. The findings in the present study, showing a greater influence on trabecular bone than on cortical bone, suggest that using the rat model of DMD reproduces the bone pathology in patients with DMD.

Our study had several limitations. First, the WT and DMD rats had different mean body weights. Second, no evaluation of muscle volume and strength, physical activity, or cytokine production (such as interleukin 6) was performed. Third, bone dynamics such as bone formation and bone resorption were not clarified. But despite those limitations, this study is the first to describe changes in trabecular and cortical bone at two age time points in DMD rats. We believe that our study provides useful basic data that will contribute to further elucidating the unknown pathology behind osteoporosis in DMD.

In conclusion, the present study clearly demonstrates that trabecular bone volume decreased significantly, with deterioration of trabecular microstructure, with age (to 30 weeks from 15 weeks) in a rat model of DMD. Cortical thickness and cortical area/total area did not differ between WT rats and DMD rats.

Acknowledgements

We thank Boldface Editors Inc. (https://www.boldfaceeditors.com) for English language editing. All authors contributed to the manuscript and approved the final version for submission. All authors are fully responsible for the content and editorial decisions of this manuscript.

Funding

This work was financially supported in part by Grants-in-Aid from the Japan Ministry of Education, Culture, Sports, Science and Technology (Scientific Research C no. 9203015 to A.S.).

Conflicts of Interest

The authors received no financial support from commercial companies for the research reported here. The authors declare that they have no conflicts of interest.

References

1. Emery AE (2002): The muscular dystrophies. Lancet 359(9307): 687−695
2. Larson CM & Henderson RC (2000): Bone mineral density and fractures in boys with Duchenne muscular dystrophy. J Pediatr Orthop 20(1): 71−74
3. Joseph S, Wang C, Di Marco M *et al* (2019): Fractures and bone health monitoring in boys with Duchenne muscular dystrophy managed within the Scottish Muscle Network. Neuromuscul Disord 29(1): 59−66
4. Perera N, Sampaio H, Woodhead H & Farrar M (2016): Fracture in Duchenne muscular dystrophy: natural history and vitamin D deficiency. J Child Neurol 31(9): 1180−1187
5. Söderpalm AC, Magnusson P, Ahlander AC *et al* (2007): Low bone mineral density and decreased bone turnover in Duchenne muscular dystrophy. Neuromuscul Disord 17(11-12): 919−928
6. Bianchi ML, Mazzanti A, Galbiati E *et al* (2003): Bone mineral density and bone metabolism in Duchenne muscular dystrophy. Osteoporos Int 14(9): 761−767
7. Wang B, Li J & Xiao X (2000): Adeno-associated virus vector carrying human minidystrophin genes effectively ameliorates muscular dystrophy in mdx mouse model. Proc Natl Acad Sci U S A 97(25): 13714−13719
8. Fabb SA, Wells DJ, Serpente P & Dickson G (2002): Adeno-associated virus vector gene transfer and sarcolemmal expression of a 144 kDa micro-dystrophin effectively restores the dystrophin-associated protein complex and inhibits myofibre degeneration in nude/mdx mice. Hum Mol Genet 11(7): 733−741
9. Gregorevic P, Allen JM, Minami E *et al* (2006): rAAV6-microdystrophin preserves muscle function and extends lifespan in severely dystrophic mice. Nat Med 12(7): 787−789
10. Nakamura K, Fujii W, Tsuboi M *et al* (2014): Generation of muscular dystrophy model rats with a CRISPR/Cas system. Sci Rep 4: 5635
11. Kanou M, Horie K, Nakamura K, Jimbo T, Sigiyama H & Yamana K (2017): Efficacy of a novel selective androgen receptor modulator (TEI-SARM2) with once weekly dosing in rat unloaded muscle atrophy and Duchenne muscular dystrophy models. J Cachexia Sarcopenia Muscle 8: 1066−1067
12. Kornegay JN (2017): The golden retriever model of Duchenne muscular dystrophy. Skelet Muscle 7(1): 9
13. Hawkins EC, Bettis AK & Kornegay JN (2020): Expiratory dysfunction in young dogs with golden retriever muscular dystrophy. Neuromuscul Disord 30(11): 930−937
14. Lau YS, Zhao L, Zhang C, Li H & Han R (2020): Genetic disruption of the inflammasome adaptor ASC has minimal impact on the pathogenesis of Duchenne muscular dystrophy in mdx mice. Life Sci 257: 118069
15. Ralbousky NM, Dey P, Galfano A, Dey BK & Lednev IK (2020): Diagnosis of a model of Duchenne muscular dystrophy in blood serum of mdx mice using Raman hyperspectroscopy. Sci Rep 10(1): 11734
16. Watanuki M, Sakai A, Sakata T *et al* (2002): Role of inducible nitric oxide synthase in skeletal adaptation to acute increases in mechanical loading. J Bone Miner Res 17(6): 1015−1025
17. Dempster DW, Compston JE, Drezner MK *et al* (2013): Standardized nomenclature, symbols, and units for bone histomorphometry: a 2012 update of the report of the ASBMR Histomorphometry Nomenclature Committee. J Bone Miner Res 28(1): 2−17
18. Bouxsein ML, Boyd SK, Christiansen BA, Guldberg RE, Jepsen KJ, Muller R (2010): Guidelines for assessment of bone microstructure in rodents using micro-computed tomography. J Bone Miner Res 25(7): 1468−1486
19. Rufo A, Del Fattore A, Capulli M *et al* (2011): Mechanisms inducing low bone density in duchenne muscular dystrophy in mice and humans. J Bone Miner Res 26(8): 1891−1903
20. Del Rocío Cruz-Guzmán O, Rodríguez-Cruz M, Almeida-Becerril T, Maldonado-Hernández J & Baeza CW (2019): Muscle function and age are associated with loss of bone mineral density in Duchenne muscular dystrophy. Muscle Nerve 59(4): 417−421
21. Li H, Lu A, Gao X *et al* (2021): Improved bone quality and bone healing of Dystrophic mice by parabiosis. Metabolites 11(4): 247
22. Misof BM, Roschger P, McMillan HJ *et al* (2016): Histomorphometry and bone matrix mineralization before and after bisphosphonate treatment in boys with Duchenne muscular dystrophy: a paired transiliac biopsy study. J Bone Miner Res 31(5): 1060−1069
23. Zheng WB, Dai Y, Hu J *et al* (2020): Effects of bisphosphonates on osteoporosis induced by Duchenne mus-

cular dystrophy: a prospective study. Endocr Pract 26(12): 1477–1485

24. Yoon SH, Chen J, Grynpas MD & Mitchell J (2016): Prophylactic pamidronate partially protects from glucocorticoid-induced bone loss in the mdx mouse model of Duchenne muscular dystrophy. Bone 90: 168–180
25. Crabtree NJ, Roper H & Shaw NJ (2022): Cessation of ambulation results in a dramatic loss of trabecular bone density in boys with Duchenne muscular dystrophy (DMD). Bone 154: 116248
26. Tung JY, Lam TP & Chan SH (2021): Bone microarchitectural alterations in boys with Duchenne muscular dystrophy on long-term glucocorticoid treatment. J Bone Miner Metab 39(4): 606–611

J UOEH 44(4)：323 − 330(2022)