

Candidal Prosthetic Hip Infection in a Patient with Previous Candidal Sepsis – A Case Report –

Yoichi MURATA¹, Satoshi OKABE^{2*}, Shogo TAMAGAWA³, Hideo OHNISHI⁴ and Akinori SAKAI¹

¹ Department of Orthopaedic Surgery, School of Medicine, University of Occupational and Environmental Health, Japan. Yahatanishi-ku, Kitakyushu 807-8555, Japan

² Department of Orthopaedic Surgery, Kitakyushu City Yahata Hospital, Ogura, Yahatahigashi-ku, Kitakyushu 805-8534, Japan

³ Department of Orthopaedic Surgery, Niigata Rosai Hospital, Touncho, Joetsu 942-8502, Japan

⁴ Department of Orthopaedic Surgery, Moji Medical Center, Higashiminatomachi, Kitakyushu 801-8502, Japan

Abstract : A 60 year-old woman with hip dysplasia battled with duodenal cancer that was complicated with *Candida tropicalis* sepsis. Two years later, the patient underwent a total hip arthroplasty (THA). She complained of a persisting low-grade fever and local heat on the THA scar. Arthrocentesis of the hip was performed and the *Candida tropicalis* was detected. Debridement and polyethylene liner/modular head exchange were performed 28 days after the primary THA. Fluconazole was administrated for one year. The patient reported no symptoms five years later. It was found that periprosthetic infection could be prevented by implant preservation surgery.

Keywords : *Candida*, total hip arthroplasty, periprosthetic joint infection.

(Received May 7, 2020, accepted June 26, 2020)

Introduction

Total hip arthroplasty (THA), one of the most effective and successful surgical techniques for treating various pathological hip conditions [1], was first reported as a clinical practice by Charnley in the 1960s [2, 3]. Despite the great success, there currently still remain multiple problems with the procedure, such as hip dislocation, polyethylene wear, and periprosthetic joint infection (PJI).

PJI is one of the greatest complications of THA, a challenge difficult to treat on many levels. A recent report indicated that the infection rate after THA is approximately 0.4 – 1.4% [4], a high risk when compared to other hip procedures. Most of the identified caus-

ative organisms include bacteria; fungal infections are rare. Azzam *et al* reported that the most commonly found cause of fungal PJI was the *Candida albicans*, discovered in fungal infections after arthroplasty [5]. In a systematic review of the hip, Fusini *et al* reported that, in 81 cases, the most frequently responsible fungal pathogens for the complication were *Candida albicans* (62.7%) and *Candida glabrata* (15.7%) [6]. An additional bacteria, *Candida tropicalis*, can exist, but has rarely been found as the cause of PJI in the hip. The diagnosis and treatment of PJI is controversial, as almost all cases involve some sort of debridement and complicated staged reimplantation of a total hip prosthesis.

*Corresponding Author: Satoshi OKABE, Department of Orthopaedic Surgery, Kitakyushu City Yahata Hospital, 2-6-2 Ogura, Yahatahigashi-ku, Kitakyushu 805-8534, Japan, Tel: +81-93-662-6565, E-mail: okabesat@gmail.com

Statement of Informed Consent

The patient was informed that data concerning the case would be submitted for publication and the patient agreed.

Case Report

In this case, a 60-year-old woman ultimately underwent a THA procedure for osteoarthritis (OA) (Figure 1A), caused by developmental dysplasia of the left hip, a diagnosis she had received many years previously. Despite the fact that the patient did not smoke, drink, or possess a family history of OA, she developed duodenal cancer at age 58, and her struggle was further complicated by the *Candida tropicalis* sepsis. After administration of medication, however, the sepsis was eventually cured. The patient's height, weight, and body mass index (BMI) were 150.5 cm, 38.0 kg and 16.8 kg/m², respectively. The preoperative clinical test items (included in the chest radiography, electrocardiogram, blood and urine exams) were normal. A preoperative physical examination of the patient suggested restricted range of motion of the hip.

The patient underwent THA surgery to correct the hip dysplasia in the left hip with the help of general anesthesia and an anterolateral approach in the supine position. Rehabilitation began two days post-surgery with no limit on weight bearing due to the low levels of pain in the patient. As there were no additional symptoms, no post-operative laboratory data, and no complications in the radiographic findings, the patient was discharged from the hospital with free gait two weeks after the operation.

During an outpatient department office visit four weeks after the THA operation, the patient began to

complain of a low grade fever (around 37°C) and local heat on the THA scar, which had persisted for one week. Macroscopic findings indicated swelling on the scar; no redness or local heating were found. No special notes about the radiographic findings were indicated (Figure 1B). Laboratory data indicated slightly high levels of inflammation (WBC 7,100/mm³ and CRP 2.7 mg/dl) and a β -D glucan level of 6.9 pg/ml (Table 1). The management team suspected a prosthetic infection and chose to perform an arthrocentesis of the patient's hip on the day the patient voiced her complaints. Macroscopic observations from the exam showed a yellow and clear synovial fluid as relative findings. During a hip aspiration in which a single microbiologic culture was taken and incubated for five days, the *Candida tropicalis* bacteria was detected. Management determined that the patient was suffering from a postoperative infection four weeks after primary surgery.

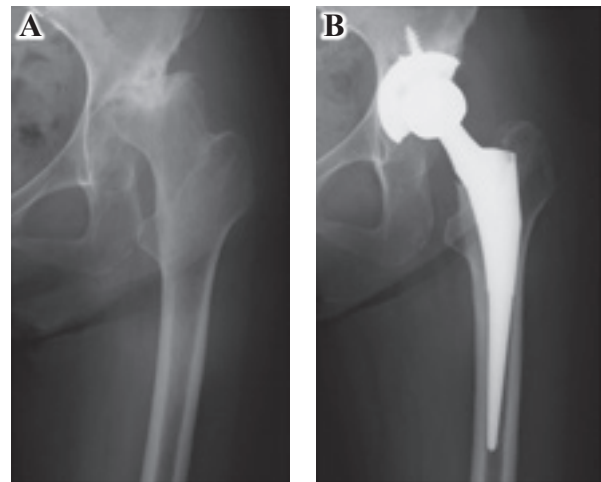


Figure 1. A: Preoperative radiograph, B: Radiograph when the patients complained symptoms (4 weeks after primary surgery).

Table 1. Changes in representative laboratory data of infection

	Pre-op (Primary)	1 wk	2 wks	4 wks	1 day	2 days	1 mo	2 mos	6 mos	1 yr	2 yrs	5 yrs
WBC (/mm ³)	6,600	6,800	6,300	7,100	6,100	4,900	4,700	4,500	4,400		4,800	4,400
CRP (mg/dl)	0.1	0.7	0.1	2.7	0.6	0.1	0	0.1	0	0.1	0	0.2
β -D glucan (pg/ml)				6.9	8	5.6	< 5.0					

WBC: white blood cell, CRP: C-reactive protein, wk: week, wks: weeks, mo: month, mos: months, yr: year, yrs: years

Twenty eight days after the THA surgery, a revision surgery was performed on the patient. Again, the surgeon used general anesthesia and an anterolateral approach in the supine position. Due to mild synovitis being observed in intraoperative findings, debridement and a polyethylene liner/femoral head exchange were performed. After this revision surgery, the patient remained bed-ridden for one week, performing rehabilitation according to her pain levels. After the patient's levels of β -D glucan lowered to a value less than 5.0 pg/ml, she could be discharged from the hospital with free gait; the patient left the hospital four weeks after revision surgery.

After this revision surgery, Fluconazole, an antibiotic, was administered intravenously (200 mg/day) for 28 days, starting from the day of the actual revision procedure. It was then taken orally for an additional six months. After the six-month period, the Fluconazole was reduced to 100 mg/day. The patient did not take any other medicine for one year after the revision surgery. Five years after the revision surgery, the patient reported no symptoms. We judged no recurrence of infection since there were no detectable findings in her blood and radiographic exams.

Discussion

A patient experienced a *Candida tropicalis* infection after THA, but received successful implant preserving treatment with an exchange polyethylene liner. To our knowledge, fungal (especially *Candida tropicalis*) hip prosthetic infections are extremely rare. Most PJI cases of fungal infection appear as compromised host infections, a possible result of complicated underlying diseases. We believe that the patient experienced no additional problems post-revision surgery because of the fact that the sepsis for *Candida tropicalis* was completely drug free and cured two years previously. However, a blood culture, measurement of β -D glucan, and prophylactic administration of an antifungal drug in the perioperative period will be performed if additional infections of the *Candida* bacteria result.

Fungal infections do not yield clear symptoms, as most cases result in normal areas for white blood cells and slightly elevated CRP levels. Due to a small array of symptoms and supportive laboratory data, a diagno-

sis of prompt arthrocentesis can be made. Previous articles described β -D glucan in the blood as an effective measure for helping diagnosis fungal infections [7]. Although this patient presented standard β -D glucan levels at the time of revision surgery, the value gradually decreased as intake of Fluconazole increased. We found β -D glucan to be an effective barometer for treating this type of infection. However, next time, we would like to examine the blood cultures of β -D glucan prior to surgery and perform antifungal therapy in a perioperative period for patients with previous candida infections.

According to previous reports, *Candida* arthritis after THA may occur several months to years after surgery. Studies have shown that the time frame can be anywhere from ten months to six years [5, 8-11]. The golden standard of care has always been two-stage revision, a treatment that has led to a rate of success of more than 70.0%. On the other hand, the success rate of only the debridement procedure has been shown to be less than 20.0% [6]. The Sanford Guide recommends resection arthroplasty as a favorable treatment. In our case, we believe success could occur by way of prosthesis preserving surgery because of the fact that the onset of the infection occurred in the acute stage. To our knowledge, this is the first report of a *Candida*-induced acute onset arthritis after THA.

We presented a case of acute onset infection of the *Candida tropicalis* bacteria after THA and could successfully cure PJI by implant preserving surgery. However, it is important to consider blood cultures or β -D glucan measurements before primary surgery and to combine the use of an anti-fungal perioperative period in the case of patients who have suffered from previous fungal infections. It was found that infectious arthritis could be prevented by an implant preservation surgery.

Acknowledgement

The authors thank Patrick Quinn for proofreading our manuscript.

Conflict of Interest

The authors declare no conflict of interest.

References

1. Reese A & Macaulay W (2003): Hybrid total hip arthroplasty: state-of-the-art in the new millennium?. *J South Orthop Assoc* 12(2): 75-78
2. Charnley J (1960): Anchorage of the femoral head prosthesis to the shaft of the femur. *J Bone Joint Surg Br* 42-B: 28-30
3. Charnley J (1961): Arthroplasty of the hip. A new operation. *Lancet* 1 (7187): 1129-1132
4. Biau DJ, Leclerc P, Marmor S *et al* (2012): Monitoring the one year postoperative infection rate after primary total hip replacement. *Int Orthop* 36(6): 1155-1161
5. Azzam K, Parvizi J, Jungkind D *et al* (2009): Microbiological, clinical, and surgical features of fungal prosthetic joint infections: a multi-institutional experience. *J Bone Joint Surg Am* 91 (Suppl 6): 142-149
6. Fusini F, Aprato A, Masse A *et al* (2020): Candida periprosthetic infection of the hip: a systematic review of surgical treatments and clinical outcomes. *Int Orthop* 44(1): 15-22
7. McKeating C, White PL, Posso R *et al* (2018): Diagnostic accuracy of fungal PCR and beta-d-glucan for detection of candidaemia: a preliminary evaluation. *J Clin Pathol* 71(5): 420-424
8. Deelstra JJ, Neut D & Jutte PC (2013): Successful treatment of *Candida albicans*-infected total hip prosthesis with staged procedure using an antifungal-loaded cement spacer. *J Arthroplasty* 28(2): 374.e5-374.e8
9. Younkin S, Evarts CM & Steigbigel RT (1984): *Candida parapsilosis* infection of a total hip-joint replacement: successful reimplantation after treatment with amphotericin B and 5-fluorocytosine. A case report. *J Bone Joint Surg Am* 66(1): 142-143
10. Ramamohan N, Zeineh N, Grigoris P & Butcher I (2001): *Candida glabrata* infection after total hip arthroplasty. *J Infect* 42(1): 74-76
11. Evans RP & Nelson CL (1990): Staged reimplantation of a total hip prosthesis after infection with *Candida albicans*. A report of two cases. *J Bone Joint Surg Am* 72(10): 1551-1553

J UOEH 42(4) : 327 - 330 (2020)
