

[Case Report]

## Rapidly Progressive Osteolysis and a Large Cystic Lesion that Destroyed the Inner Table of the Iliac Bone Following Cementless Total Hip Arthroplasty: A Case Report

Daishi HAMADA<sup>1</sup>, Toshiharu MORI<sup>1\*</sup>, Manabu TSUKAMOTO<sup>1</sup>, Yoshiaki YAMANAKA<sup>1</sup>, Soshi UCHIDA<sup>2</sup> and Akinori SAKAI<sup>1</sup>

<sup>1</sup> Department of Orthopaedic Surgery, School of Medicine, University of Occupational and Environmental Health, Japan. Yahatanishi-ku, Kitakyushu 807-8555, Japan

<sup>2</sup> Department of Orthopaedic Surgery, Wakamatsu Hospital for the University of Occupational and Environmental Health, Japan. Wakamatsu-ku, Kitakyushu 808-0024, Japan

**Abstract:** We report a case of rapidly progressive osteolysis and a very large cystic lesion that destroyed the inner table of the iliac bone following cementless total hip arthroplasty (THA). A 59-year-old female patient developed left hip pain at 11 years after THA. Osteolysis surrounding the acetabular cup was pointed out. She was brought to our hospital by ambulance due to severe left hip pain at 12 years after THA. Computed tomography (CT) showed that a cystic lesion in the pelvic cavity had destroyed the inner table of the iliac bone. Magnetic resonance imaging (MRI) showed a high signal intensity area of the hemorrhagic cystic lesion in the iliac bone in both T1-weighted and T2-weighted images. She underwent a liner and femoral head exchange, and required bone grafting and revision of the cup. The cystic lesion was removed and block-like allograft bone grafts were stuffed into the bone defects. If osteolysis and cystic lesions occur at the same time, not only the bone area around the implant but also a distant area like the inner table of the iliac bone may be destroyed. Additional tests such as CT or MRI may be useful to detect the presence of distant or cystic lesions. Early diagnosis and treatment are important because severe complications may occur in cases where osteolysis and cystic lesions coexist after THA.

**Keywords:** total hip arthroplasty, osteolysis, cystic lesion, inner table of the iliac bone.

(Received May 11, 2018, accepted November 9, 2018)

### Introduction

Osteolysis surrounding prosthesis has been defined as a complication that is caused by wear debris, and it can affect the clinical outcome of total hip arthroplasty (THA) [1]. The biological response to polyethylene wear debris is complicated and many unanswered questions remain. In general, polyethylene wear debris causes the formation of a soft tissue mass as a result

of an inflammatory reaction. Some cases with cystic or tumorous lesions have also been reported [2–6], and it has been suggested that cystic lesions after THA may be an early sign of wear debris [7]. We report an unusual case of a rapidly progressive osteolysis and a cystic lesion that destroyed the inner table of the iliac bone and occurred secondary to a cementless total hip arthroplasty (THA) 12 years after surgery.

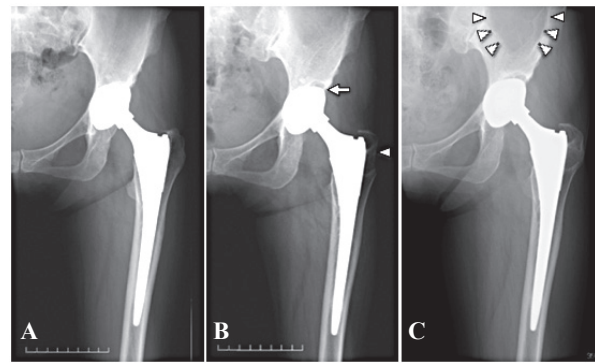
\*Corresponding Author: Toshiharu MORI, Department of Orthopaedic Surgery, Shin-kokura Hospital, 1-3-1 Kanada, Kokurakita-ku, Kitakyushu 803-8505, Japan, Tel: +81-93-571-1031, Fax: +81-93-591-0580, E-mail: shunyou@med.uoeh-u.ac.jp

### Case report

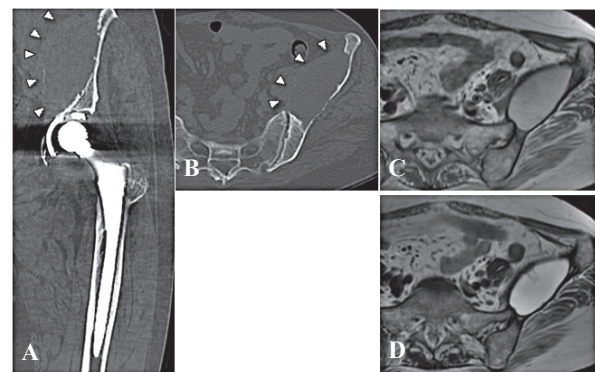
A 59-year-old female patient with a 10-year history of osteoporosis had undergone left total hip arthroplasty (THA) using the Synergy<sup>®</sup> cementless system with non-cross-linked ultra-high molecular weight polyethylene (Smith & Nephew, Memphis, TN) for osteoarthritis at the age of 47 (Fig.1A). Left hip joint pain appeared and gradually worsened at 11 years after surgery. The plain anterior-posterior pelvis view showed osteolysis surrounding the acetabular cup. At this time, there was no evidence of osteolytic lesion in the left iliac bone (Fig.1B). The patient was brought to our hospital by ambulance due to severe left hip pain at 12 years after the initial THA.

There was no definitive clinical evidence of infection such as fever, increased white blood cell count, or erythrocyte sedimentation rate. A bacterial culture for synovial fluid was also negative. The serum level of tartrate-resistant acid phosphatase 5b (TRACP-5b), a bone resorption marker, was abnormally high (655 mU/dl; normal range 120–420 mU/dl), despite the fact that the patient had taken alendronate for 10 years. Radiographs showed a huge osteolytic lesion in the left iliac bone and expanded osteolysis. The femoral head of the left THA was subtly eccentric relative to the central point of the cup due to excessive wear of the polyethylene (Fig.1C). Computed tomography (CT) showed that a cystic lesion in the pelvic cavity had destroyed the inner table of the iliac bone. Magnetic resonance imaging (MRI) showed a high signal intensity area of the hemorrhagic cystic lesion in the iliac bone in both T1-weighted and T2-weighted images (Fig.2).

She underwent a liner and femoral head exchange, and required bone grafting and revision of the cup (Trabecular metal cup<sup>®</sup>; Zimmer, Warsaw, IN). There was no trunnionosis at the femoral head–neck interface. The liner was partially worn, and we observed loosening of the cup. We also observed a bone-defect site in the anterior wall of the acetabulum, which led from the screw hole of the acetabular cup. The bone-defect site in the anterior wall had then expanded into the cystic lesion in the inner table of the iliac bone. A large amount of brown liquid flowed out from the cystic lesion. There were bone defects at the acetabular anterior wall and fossa (Paprosky classification type 2A), which we

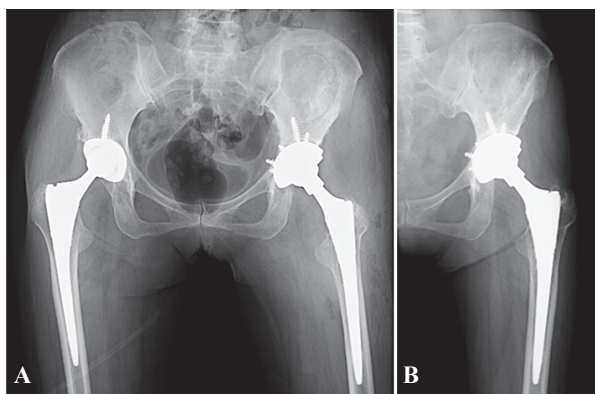


**Fig. 1. Progression of preoperative plain radiographs.** A. Postoperative radiograph after left primary total hip arthroplasty (THA) with non-cross-linked ultra-high molecular weight polyethylene (UHMWPE). B. The 11-year follow-up radiograph after surgery. Cup side: osteolysis in Zone 1 (arrow), Stem side: osteolysis in Zone 1 (arrow-head). C. The 12-year follow-up radiograph after surgery (just before revision THA). This radiograph showed a huge osteolytic lesion in the left iliac (arrowheads) and expanded osteolysis in Zone 1 of cup side. The femoral head was eccentric relative to the central point of the cup because of excessive wear of the polyethylene. UHMWPE: ultra-high molecular weight polyethylene.



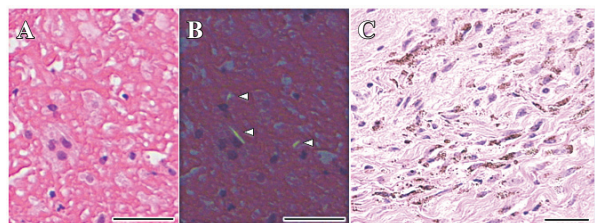
**Fig. 2. Preoperative CT and MRI.** The CT findings on A. coronal view, B. axial view demonstrated a pseudotumoral mass that destroyed the inner plate of the iliac bone (arrowheads). The MRI findings on C. T1-weighted image and D. T2-weighted image showed a hemorrhagic cystic lesion, which indicated high signal intensity in both T1-weighted and T2-weighted images, in the ilium.

reconstructed with a larger acetabular cup. We changed the patient's position from lateral to supine to approach the inner table of the iliac bone. The cystic lesion was removed by hand, and block-like allograft bone grafts were stuffed into the bone defects (Fig.3A).



**Fig. 3. Progression of plain radiographs after revision total hip arthroplasty.** A. The postoperative radiograph. B. The 2-year follow-up radiograph after revision THA. No findings of loosening and expanded osteolysis were present at cup and stem side. The allogenic bone graft in the left ilium is assimilating. THA: total hip arthroplasty.

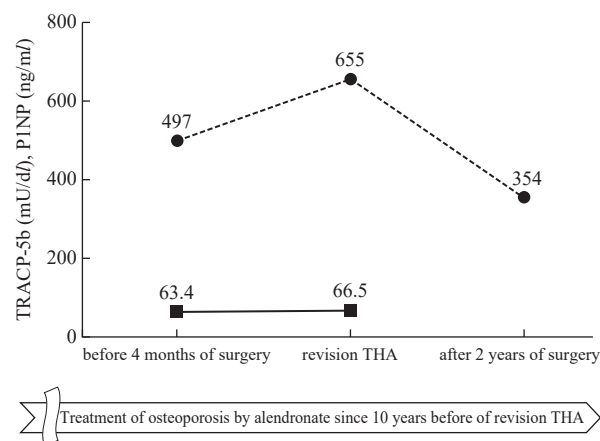
Histopathological findings in the extracted tissue showed multinucleated giant cells containing large polyethylene wear debris, as well as macrophages (Fig.4A). There were no multinucleated giant cells containing metal particles. Hemosiderin was present in the interstitium of the tissue, and chronic inflammatory cells were also observed (Fig.4B).



**Fig. 4. Histopathological findings in the tissue exacted by revision total hip arthroplasty.** A. Abundant macrophages were observed. B. Polyethylene particles (white arrowheads) in macrophages were visible under polarized light micrograph. C. Hemosiderin was present in the interstitium of the tissue, and infiltration of chronic inflammatory cells was observed. The hematoxylin and eosin. Scale bars: 50  $\mu$ m.

The patient was allowed to initiate weight bearing with a T-cane at three weeks after surgery. At three months after revision THA, the transplanted bone had a tendency toward bone adhesion with the iliac bone and we observed no progress of the osteolysis lesion. The serum level of

TRACP-5b returned to normal (354 mU/dl) within two years after reoperation (Fig.5). At two years after surgery, the transplanted bone grafts were assimilating (Fig.3B) and the patient was able to walk without assistance.



**Fig. 5. Transition of bone resorption markers.** Serum levels of tartrate-resistant acid phosphatase-5b (TRACP-5b) increased as the preoperative osteolytic lesion progressed despite taking alendronate every week. It returned to the reference range within 2 years after revision total hip arthroplasty (THA). TRACP-5b: tartrate-resistant acid phosphatase-5b (mU/dl), P1NP: procollagen type 1 N-terminal propeptide (ng/ml), ●: TRACP-5b, ■: P1NP.

### Discussion

The most important findings of this case report are that osteolysis and accompanying enlargement of the cyst expanded rapidly, destroying not only the periprosthetic bone but also the iliac bone, and that the serum TRACP-5b in this case was abnormally high before revision THA but returned to a normal level within two years after the surgery.

Our diagnosis was based on radiographic and histological findings as follows. First, a cystic lesion around the implants had formed due to polyethylene wear after THA. Second, the supply of sustained polyethylene wear debris and the inflammatory reaction due to intracystic hemorrhage or hemosiderin deposit caused rapidly progressive osteolysis and a cystic lesion that destroyed the inner table of the iliac bone. The differential diagnosis in our patient was a pelvic tumorous lesion and adverse reaction to metal debris, but these

were excluded based on the intraoperative and histopathological findings.

Osteolysis surrounding prosthesis has been defined as a complication that is caused by wear debris, and affects the clinical outcome of THA [1]. There are many reports of osteolysis and accompanying enlargement of the cyst [2–7], but few reports present pathological findings [2, 3]. The pathological findings of our case indicated that there were polyethylene particle-like substances in abundant macrophages, and hemosiderin was present in the interstitium of the tissue. Wan *et al* have reported that size progression of osteolysis is slow in simple X-ray images (average rate of 0.89 mm/year) [8], but several studies have reported that deposition of hemosiderin is a chronic inflammatory finding and the presence of a large amount of blood in the cyst reflects the rapid expansion of the lesion [9]. Thus, the findings of this case (presence of polyethylene particles and hemosiderin) do not contradict the causative factors in the rapidly progressive periprosthetic osteolysis and cystic lesion. It is important that we make an early diagnosis of progressive osteolysis after THA, because there may be severe complications in cases where hematoma and hemosiderin deposits coexist in osteolysis, such as cystic tumor increase, urinary obstruction disorder, femoral nerve paralysis, sciatic nerve paralysis and abdominal organ pressure [2, 3, 5, 7].

It is often difficult to predict the progression of osteolysis because most cases are asymptomatic [10]. Engh *et al* reported that a clinically important osteolytic area is defined as 1.5 cm<sup>2</sup> or greater [11–13]. One study has suggested that X-ray imaging underestimates the incidence and degree of periprosthetic osteolysis, and CT is a simple alternative for follow-up evaluation [14]. So as not to underestimate the osteolysis, it is necessary to diagnose the osteolytic area exactly. On the other hand, it has been recognized that osteolysis is usually recognized periprosthetically, and has been evaluated in the neighborhood on the cup and stem side [15, 16]. However, when a cystic lesion occurs, as in this case, not only the bone region surrounding the implants but also distant matter, such as the inner table of the iliac bone, may be destroyed, making it necessary to pay attention to areas other than the periprosthetic. In our case, the evaluation by CT scan was

very useful for detecting the cystic lesion in a distant region.

The serum level of TRACP-5b has been defined as a marker of osteoclast activity [17]. Whether TRACP-5b is useful as a surrogate marker of loosening or osteolysis detection remains unknown [18, 19]. In the present case, the serum level of TRACP-5b gradually increased with the progression of bone destruction despite oral administration of alendronate for at least 10 years. Furthermore, the serum level of TRACP-5b dramatically improved to within the reference range at two years after revision THA. Based on the aforementioned results, it is possible that TRACP-5b transition reflects bone resorption due to osteolysis and the accompanying enlargement of the cyst. There is no report about the relationship between sequential changes of serum TRACP-5b and osteolysis volume, and these findings about serum TRACP-5b are interesting. If an abnormal elevation of serum TRACP-5b level is observed after THA, we should be mindful that THA patients may have rapidly progressive osteolysis.

## Conclusion

We reported an unusual case of a rapidly progressive periprosthetic osteolysis and a cystic lesion that destroyed the inner table of the iliac bone and occurred secondary to a cementless THA. When osteolysis and a cystic lesion occur together, not only the bone region surrounding the implants but also distant regions, such as the inner table of the iliac bone, may be destroyed, and it is also necessary to pay attention to areas other than the hip joint. If a patient shows symptoms such as pain or discomfort after THA, an additional examination such as CT or MRI will be helpful for detecting the presence of distant lesions.

## Conflict of Interest

No potential conflicts of interest are disclosed.

## References

1. Amstutz HC, Campbell P, Kossovsky N & Clarke IC (1992): Mechanism and clinical significance of wear debris-induced osteolysis. *Clin Orthop Relat Res* 276: 7–18

2. Jeanrot C, Ouaknine M, Anract P, Forest M & Tomeno B (1999): Massive pelvic and femoral pseudotumoral osteolysis secondary to an uncemented total hip arthroplasty. *Int Orthop* 23: 37–40
  3. Hananouchi T, Saito M, Nakamura N, Yamamoto T & Yonenobu K (2005): Huge pelvic mass secondary to wear debris causing ureteral obstruction. *J Arthroplasty* 20: 946–949
  4. Beksaç B, Tözün R, Baktiroglu S, Şener N & Gonzalez Della Valle A (2007): Extravascular compression of the femoral vein due to wear debris-induced iliopsoas bursitis: a rare cause of leg swelling after total hip arthroplasty. *J Arthroplasty* 22: 453–456
  5. Fokter SK, Repse-Fokter A & Takac I (2009): Case report: femoral neuropathy secondary to total hip arthroplasty wear debris. *Clin Orthop Relat Res* 467: 3032–3035
  6. Liman J, von Gottberg P, Bahr M & Kermer P (2011): Femoral nerve palsy caused by ileopectineal bursitis after total hip replacement: a case report. *J Med Case Rep* 5: 190
  7. Mert M, Oztürkmen Y, Unkar EA, Erdogan S & Uzümçügil O (2013): Sciatic nerve compression by an extrapelvic cyst secondary to wear debris after a cementless total hip arthroplasty: A case report and literature review. *Int J Surg Case Rep* 4: 805–808
  8. Wan Z & Dorr LD (1996): Natural history of femoral focal osteolysis with proximal ingrowth smooth stem implant. *J Arthroplasty* 11: 718–725
  9. Mayo-Smith W, Rosenthal DI, Rosenberg AE & Harris WH (1993): Case report 816: Rapid acceleration of osteolysis from loose cemented total hip replacement. *Skeletal Radiol* 22: 619–621
  10. Learmonth ID, Hussell JG & Grobler GP (1996): Unpredictable progression of osteolysis following cementless hip arthroplasty. 24 femoral components followed for 6–10 years. *Acta Orthop Scand* 67: 245–248
  11. Engh CA Jr, Hopper RH Jr, Huynh C, Ho H, Sritulanondha S & Engh CA Sr (2012): A prospective, randomized study of cross-linked and non-cross-linked polyethylene for total hip arthroplasty at 10-year follow-up. *J Arthroplasty* 27 (8 Suppl): 2–7
  12. Tsukamoto M, Ohnishi H, Mori T, Kawasaki M, Uchida S & Sakai A (2017): Fifteen-year comparison of wear and osteolysis analysis for cross-linked or conventional polyethylene in cementless total hip arthroplasty for hip dysplasia- a retrospective cohort study. *J Arthroplasty* 32: 161–165.e1
  13. Tsukamoto M, Mori T, Ohnishi H, Uchida S & Sakai A (2017): Highly cross-linked polyethylene reduces osteolysis incidence and wear-related reoperation rate in cementless total hip arthroplasty compared with conventional polyethylene at a mean 12-year follow-up. *J Arthroplasty* 32: 3771–3776
  14. Sandgren B, Crafoord J, Garellick G, Carlsson L, Weidenhielm L & Olivecrona H (2013): Computed tomography vs. digital radiography assessment for detection of osteolysis in asymptomatic patients with uncemented cups: a proposal for a new classification system based on computer tomography. *J Arthroplasty* 28: 1608–1613
  15. DeLee JG & Charnley J (1976): Radiological demarcation of cemented sockets in total hip replacement. *Clin Orthop Relat Res* 121: 20–32
  16. Gruen TA, McNeice GM & Amstutz HC (1979): “Modes of failure” of cemented stem-type femoral components: a radiographic analysis of loosening. *Clin Orthop Relat Res* 141: 17–27
  17. Habermann B, Eberhardt C, Feld M, Zichner L & Kurth AA (2007): Tartrate-resistant acid phosphatase 5b (TRAP 5b) as a marker of osteoclast activity in the early phase after cementless total hip replacement. *Acta Orthop* 78: 221–225
  18. Savarino L, Avnet S, Greco M, Giunti A & Baldini N (2010): Potential role of tartrate-resistant acid phosphatase 5b (TRACP 5b) as a surrogate marker of late loosening in patients with total hip arthroplasty: a cohort study. *J Orthop Res* 28: 887–892
  19. Maier GS, Eberhardt C, Strauch M, Kafchitsas K & Kurth AA (2014): Is tartrate-resistant acid phosphatase 5b a potent bio-marker for late stage aseptic implant loosening? *Int Orthop* 38: 2597–2600
-

## 腸骨内板の破壊を伴い巨大嚢胞性病変を有する急速進行性骨溶解を発症したセメントレス人工股関節全置換術の1例

濱田 大志<sup>1</sup>, 森 俊陽<sup>1</sup>, 塚本 学<sup>1</sup>, 山中 芳亮<sup>1</sup>, 内田 宗志<sup>2</sup>, 酒井 昭典<sup>1</sup>

<sup>1</sup>産業医科大学 医学部 整形外科学教室

<sup>2</sup>産業医科大学若松病院 整形外科

**要 旨**：セメントレス人工股関節全置換術(THA)の術後に、腸骨内板の破壊を伴った巨大な嚢胞性病変を有する急速進行性の骨溶解を認めた1例を経験した。59歳の女性患者で、THA術後11年で左股関節痛が出現、その時点で寛骨カップ周囲に骨溶解を指摘された。術後12年で強い左股関節痛のために救急搬送された。コンピュータ断層撮影(CT)では、骨盤腔内の嚢胞性病変が腸骨内板を破壊しており、磁気共鳴画像法(MRI)は、T1強調画像およびT2強調画像ともに、腸骨の出血性嚢胞性病変の高い信号強度領域を示した。ライナーとヘッド交換に加え、骨移植とカップの再置換を要した。また嚢胞性病変を除去し、腸骨内板に塊状同種骨移植を行った。骨溶解および嚢胞性病変が同時期に生じた場合、病変による骨組織の破壊は、インプラント周囲のみにとどまらず、インプラントから遠く離れた部位(腸骨翼や腸骨内板など)にも及ぶ可能性がある。遠隔または嚢胞性病変の存在を検出するために、CTまたはMRIの追加検査が有用と考えられた。THAに伴う骨溶解および嚢胞性病変が共存する場合に重度の合併症が起こるため、早期の診断と治療が重要である。

**キーワード**：人工股関節全置換術, 骨溶解, 嚢腫病変, 腸骨内板.